



Patient Information

Patient name	XXXXXXXXXXXXXXXXXXXX
Patient ID	XXXXXXXXXXXXXXXXXXXX
Gender	M
Date of Birth	XXXXXXXXXXXXXXXXXXXX
Phone number	

Date of study: 12/19/2015

Indication:

Rule out coronary artery disease.

Technique:

Technique: After bolus injection of IV contrast material followed by saline bolus, limited FOV volumetric data of the heart was obtained and reconstructed into axial images.

Retrospective gating was performed, the source axial images were reformatted in multiple projections including MPR, MIP and 3D volume rendered techniques for visualization of the coronary arteries and cardiac anatomy

Findings::

Gross cardiac anatomy::

Ventricles: The ventricles are normal in shape with normal wall thickness without aneurysm or mass.

Great arteries: The great arteries are in normal anatomical relationship without stenosis or coarctation.

Pericardium: There is no evidence of pericardial thickening or a significant pericardial effusion.

Venous Anatomy: The coronary sinus is grossly normal, however, these images were not optimized for venous visualization.

Valves: There is a normal 3 cusped aortic and pulmonic valve. The mitral and tricuspid valves are grossly normal; however, vegetations cannot be ruled out by cardiac CT. There are no valve calcifications.

Findings: *Due to heavy calcific plaque, overall evaluation is somewhat limited due to blooming artifacts.*

	Proximal	Mid	Distal
LM	25% - 50%		
LAD	75% - 100%	50-75%	25% - 50%
LCX	75% - 100%	50-75%	Normal
RCA	75% - 100%	25% - 50%	Normal
Diagonal.2	>50%		
Marginal.1	>50% (1)		



USARAD.com
RADIOLOGY-ON-DEMAND®

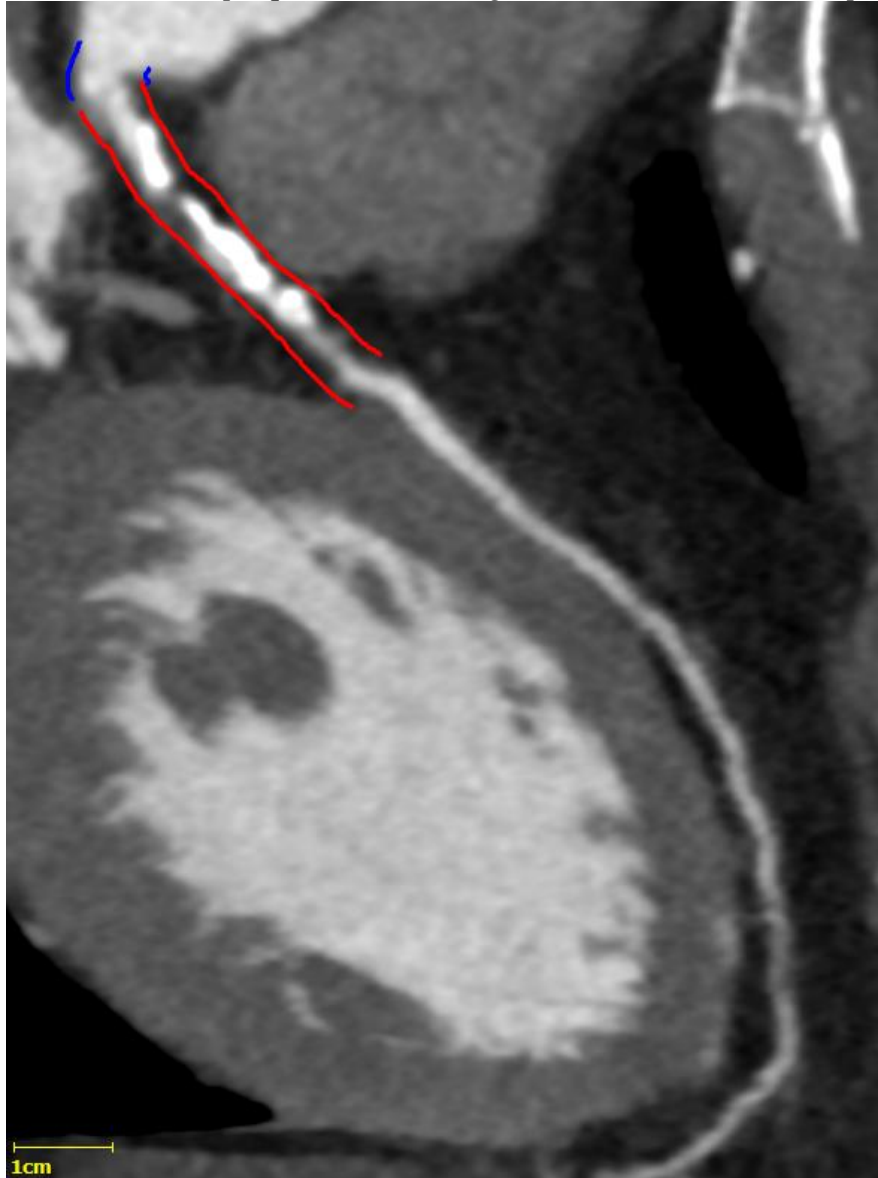


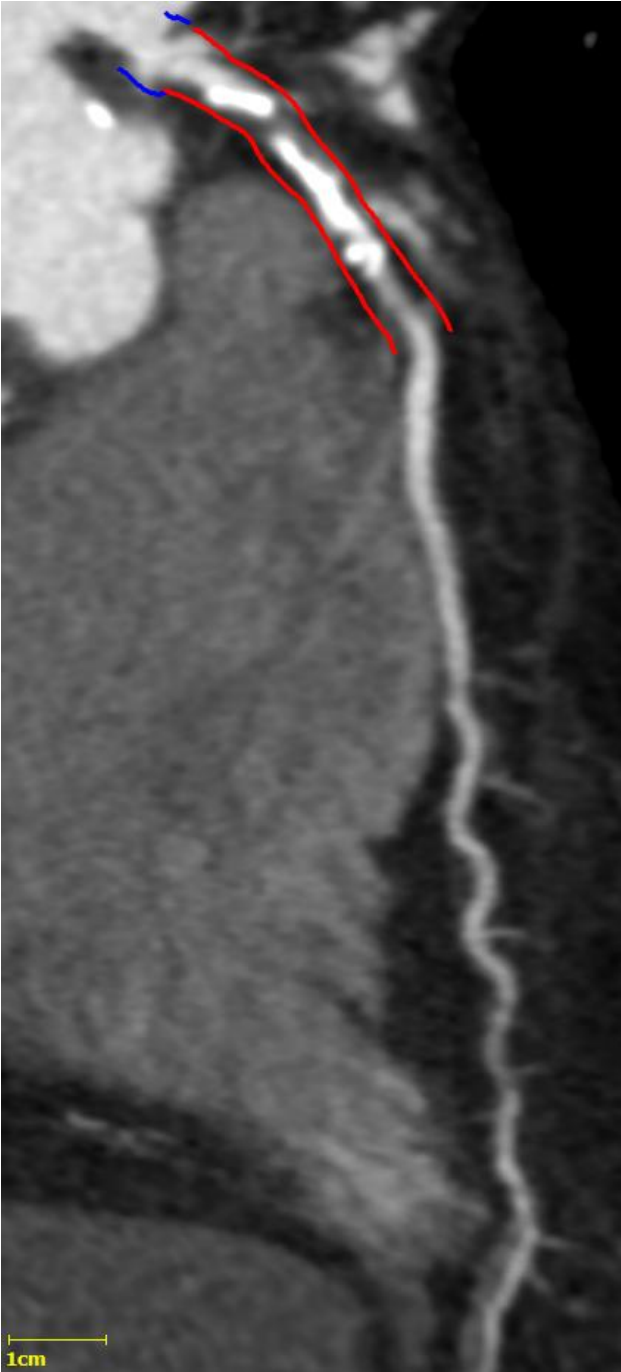
**SECOND
OPINIONS**
FOR YOUR PEACE OF MIND®

LM+LAD:

There is a Mixed plaque lesion causing 25-50% stenosis in LM .

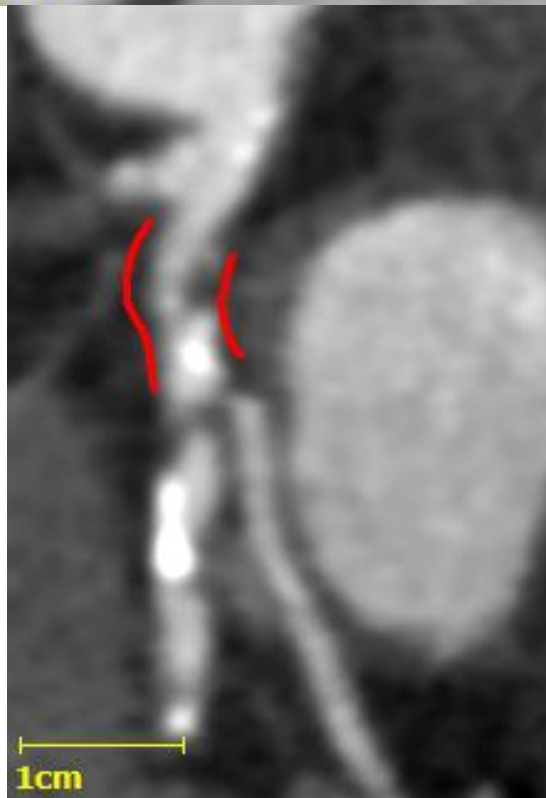
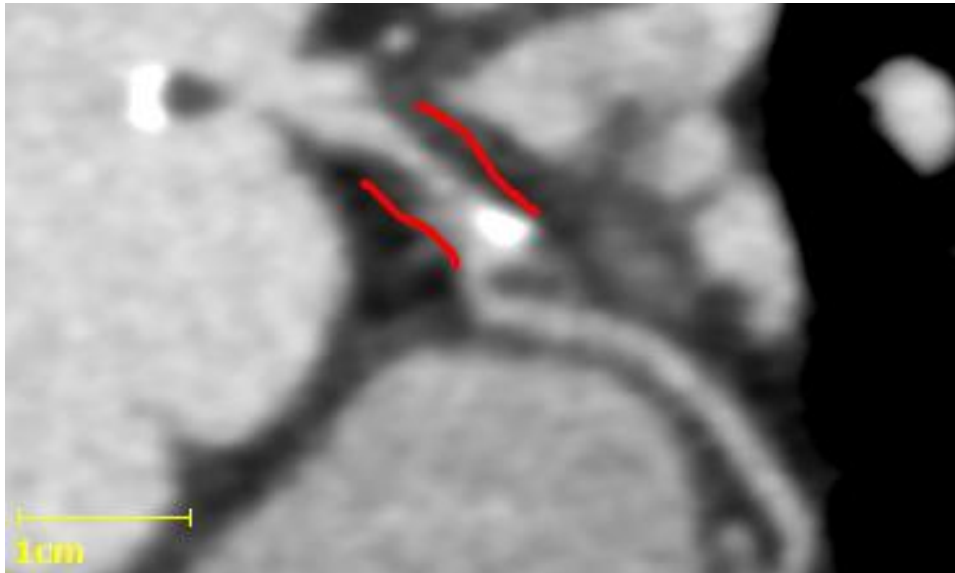
There is a Mixed plaque lesion causing 75-100% stenosis in LAD proximal section.





LCX:

There is a Mixed plaque lesion causing 75-100% stenosis proximal section.



RCA:

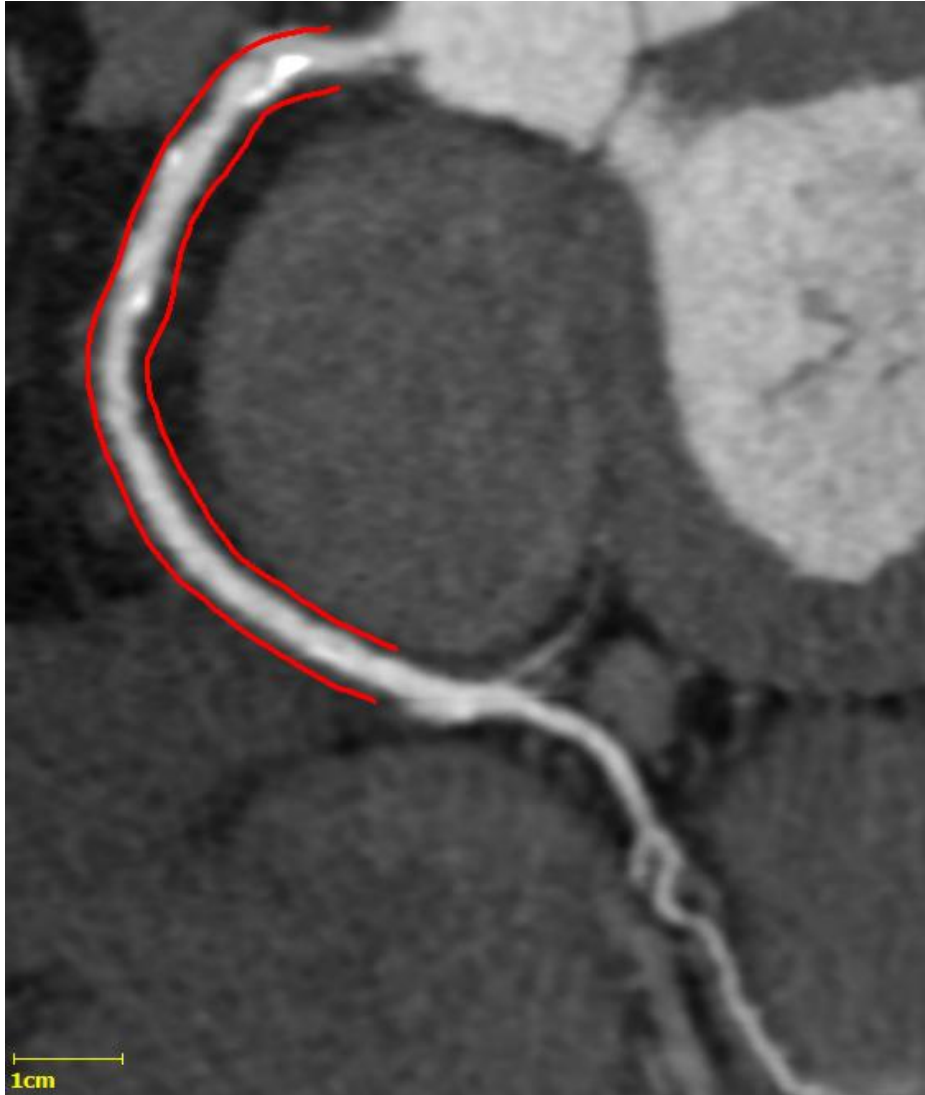
There is a Mixed plaque lesion causing 75-100% stenosis proximal section.



USARAD.com
RADIOLOGY-ON-DEMAND®



**SECOND
OPINIONS**
FOR YOUR PEACE OF MIND®

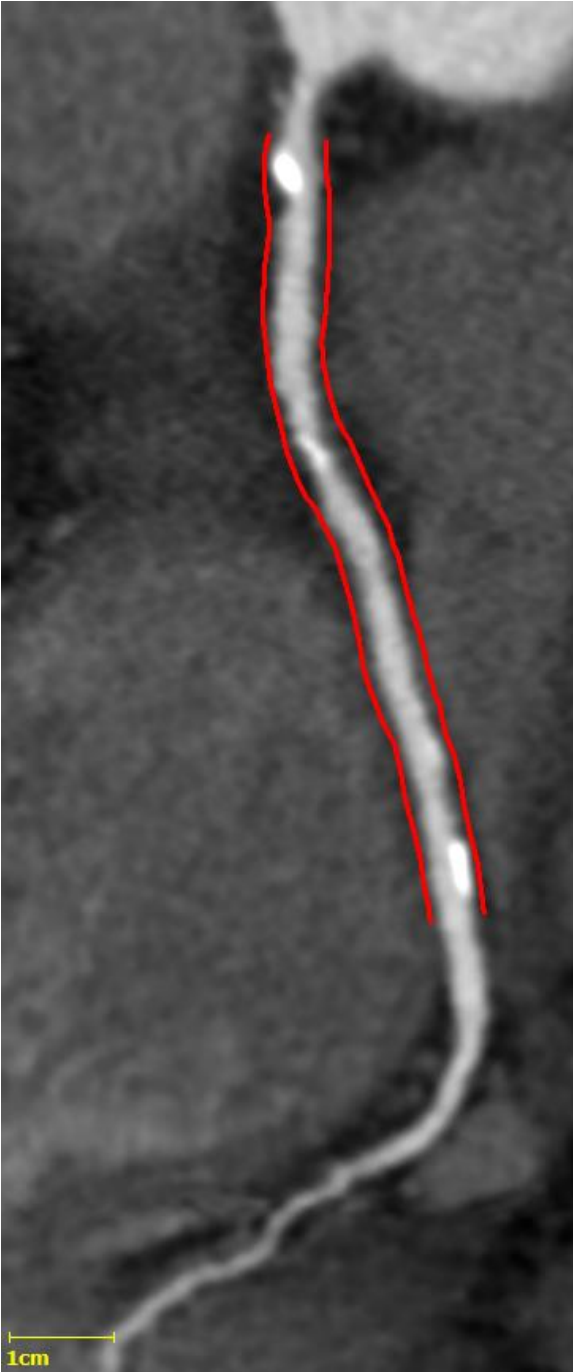




USARAD.com
RADIOLOGY-ON-DEMAND®

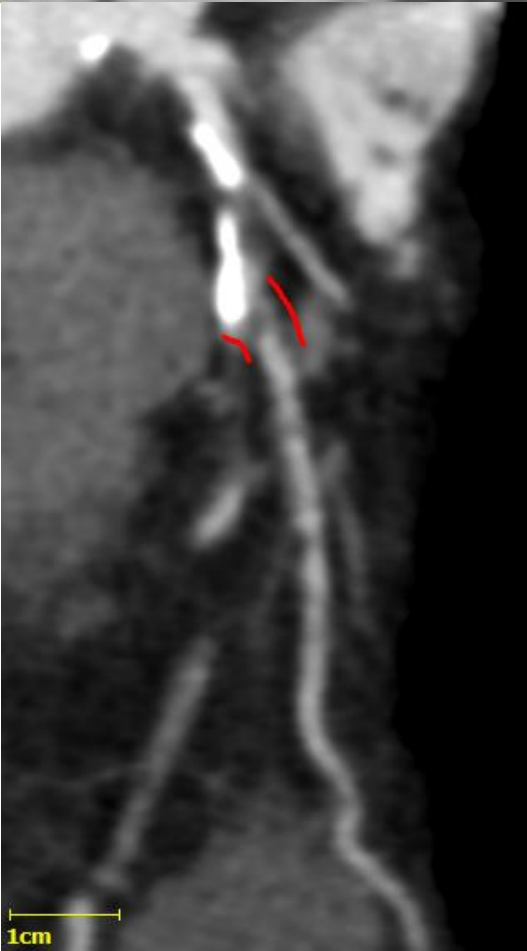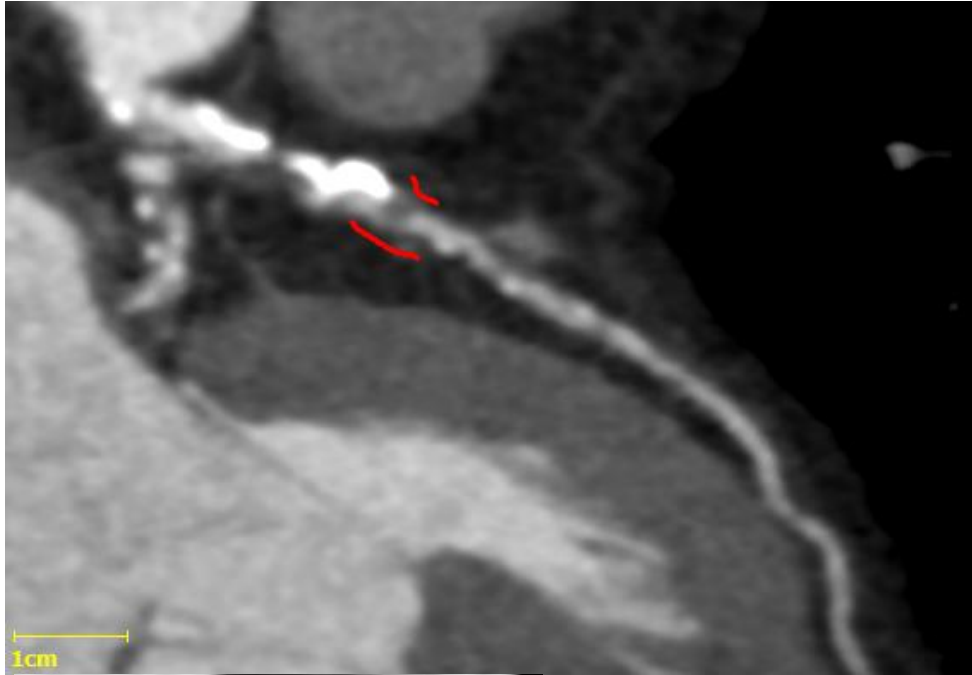


**SECOND
OPINIONS**
FOR YOUR PEACE OF MIND®



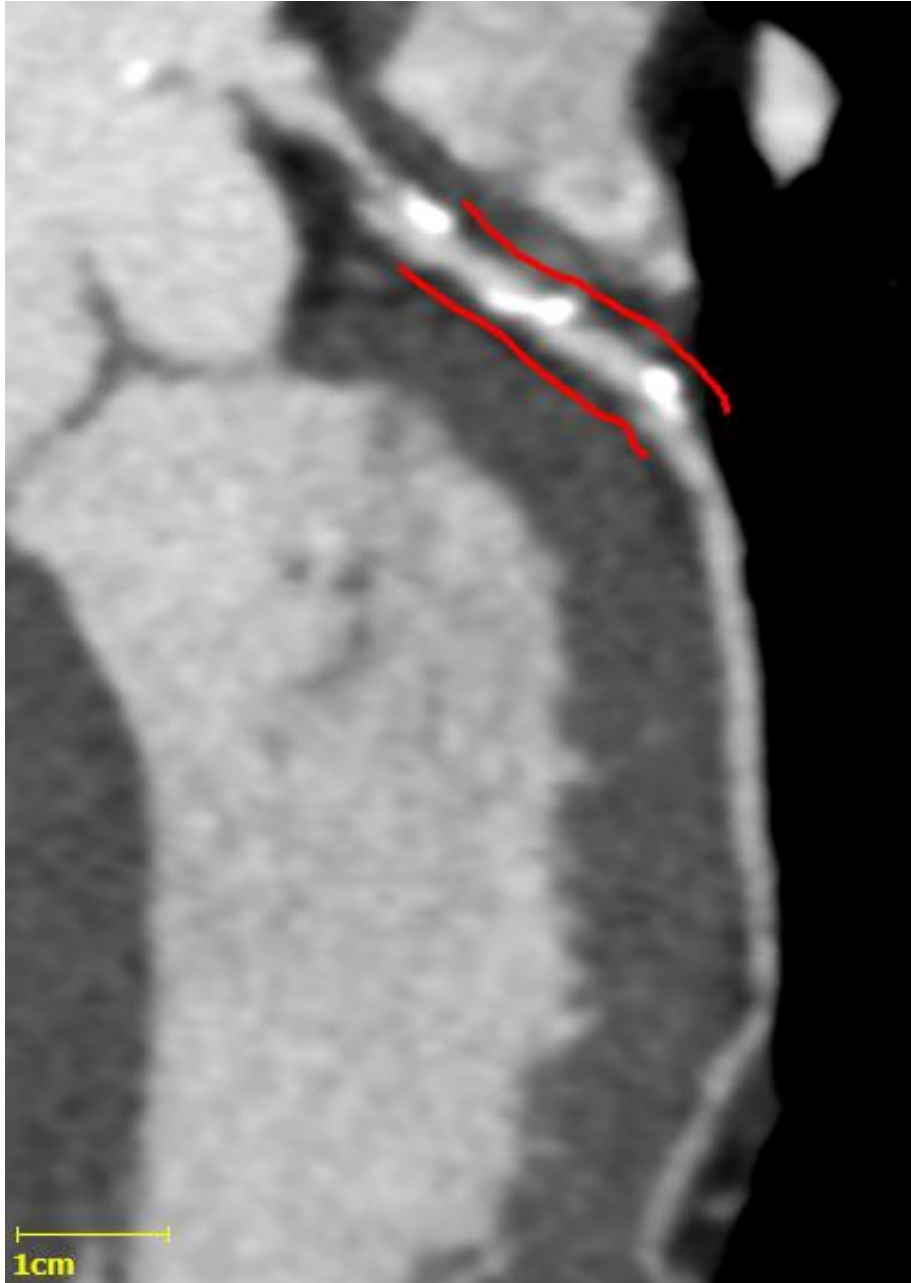Diagonal.2:

There is a non-CA plaque lesion causing >50% stenosis .



Marginal.1:

There is a Mixed plaque lesion causing >50% stenosis .

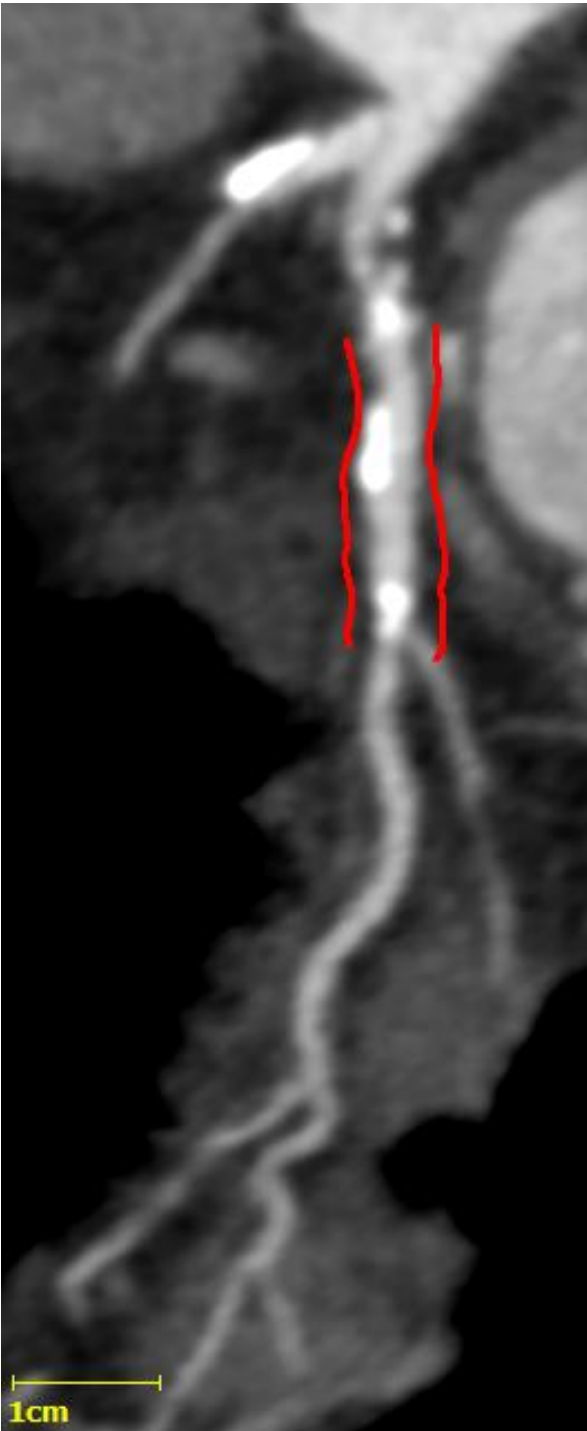



USARAD.com
RADIOLOGY-ON-DEMAND®



**SECOND
OPINIONS**
FOR YOUR PEACE OF MIND®



Extracardiac findings: (PLEASE NOTE - Only limited evaluation of extracardiac structures is possible due to small field of view.)

Mediastinum: There is no mediastinal adenopathy.



Lungs: The limited evaluation of the lungs reveal no abnormalities. There is no mass, infiltrate, or effusion. There is mild dependent subsegmental atelectasis bilaterally.

Aorta and pulmonary arteries: No evidence for a large central PE within visualized vessels. Aorta is grossly unremarkable.

Upper abdomen: The liver and other visualized upper abdominal organs are unremarkable.

Bones and Chest Wall: There are no lytic or blastic bone lesions. The chest wall is unremarkable.

Impression:

LM+LAD:

There is a Mixed plaque lesion causing 25-50% stenosis in LM .

There is a Mixed plaque lesion causing 75-100% stenosis in LAD proximal section.

LCX:

There is a Mixed plaque lesion causing 75-100% stenosis proximal section.

RCA:

There is a Mixed plaque lesion causing 75-100% stenosis proximal section.

Diagonal.2:

There is a non-CA plaque lesion causing >50% stenosis .

Marginal.1:

There is a Mixed plaque lesion causing >50% stenosis .

Recommendation:

Further evaluation with conventional angiography.

Thank you for your kind referral.

*Electronically Signed by Michael Yuz, MD,
Diplomate, American Board of Radiology
Diplomate, Society of Cardiovascular Computed Tomography*

Report Date: 12/19/2015

Report Time: 5:55 AM

Powered by RCadia COR Analyzer