



Patient Information

Patient name	XXXXXXXXXXXX
Patient ID	FP00007773
Gender	F
Date of Birth	9/12/1949
Phone number	

Referring physician Information

Physician	
Phone	
Address	

Date of study: 11/24/2015

Indication:

Rule out coronary artery disease.

Technique: After bolus injection of IV contrast material followed by saline bolus, limited FOV volumetric data of the heart was obtained and reconstructed into axial images.

Retrospective gating was performed, the source axial images were reformatted in multiple projections including MPR, MIP and 3D volume rendered techniques for visualization of the coronary arteries and cardiac anatomy.

Findings:

Gross cardiac anatomy:

Ventricles: The ventricles are normal in shape with normal wall thickness without aneurysm or mass.

Great arteries: The great arteries are in normal anatomical relationship without stenosis or coarctation.

Pericardium: There is no evidence of pericardial thickening or a significant pericardial effusion.

Venous Anatomy: The coronary sinus is grossly normal, however, these images were not optimized for venous visualization.

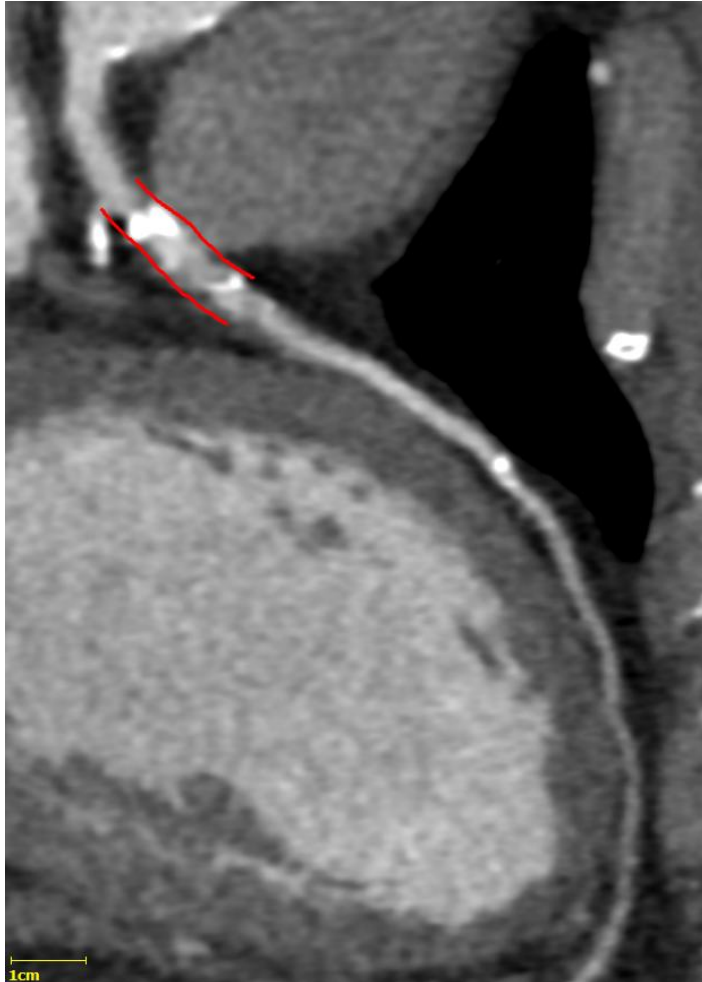
Valves: There is a normal 3 cusped aortic and pulmonic valve. The mitral and tricuspid valves are grossly normal; however, vegetations cannot be ruled out by cardiac CT. There are no valve calcifications.

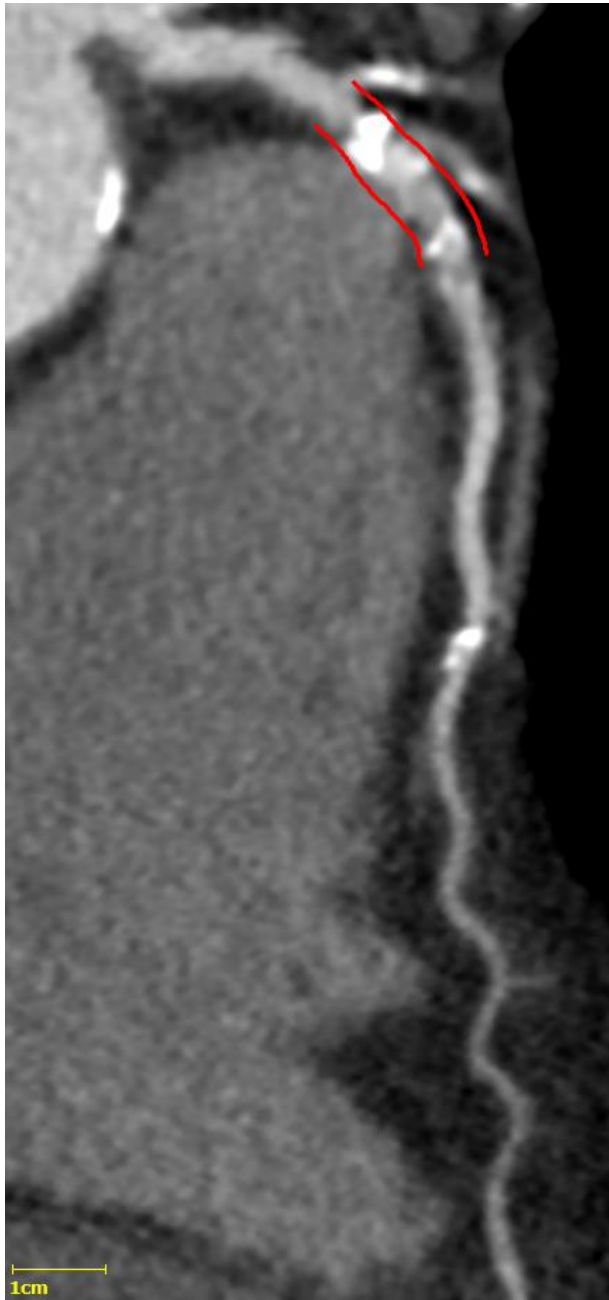
Coronary anatomy:

	Proximal	Mid	Distal
LM	Normal		
LAD	Normal	50% - 75% (1)	Normal
LCX	Normal	25% - 50% (1)	Normal
RCA	Normal	Normal	Normal
Diagonal.2	50% - 75% (1)		
Diagonal.1	>50% (1)		

LM+LAD:

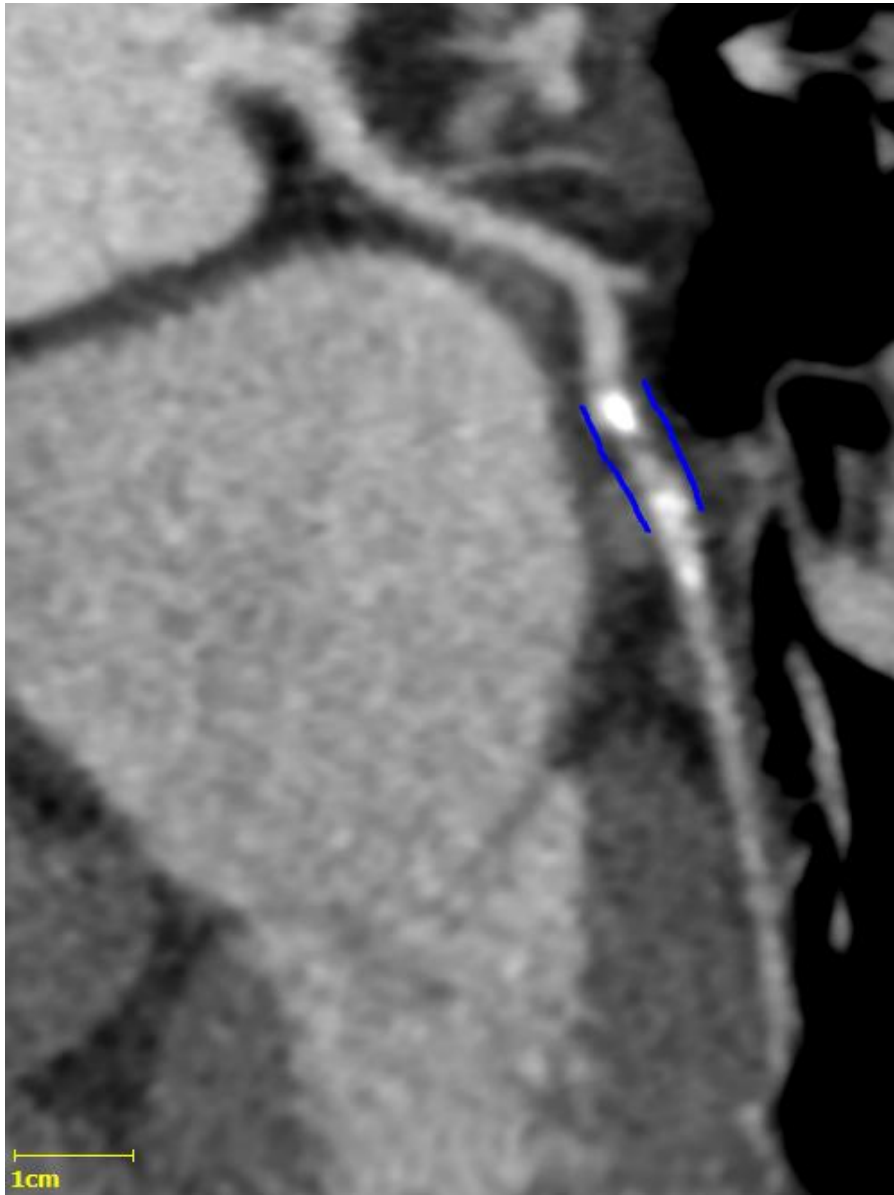There is a Mixed plaque lesion causing 50-75% stenosis in LAD mid section.

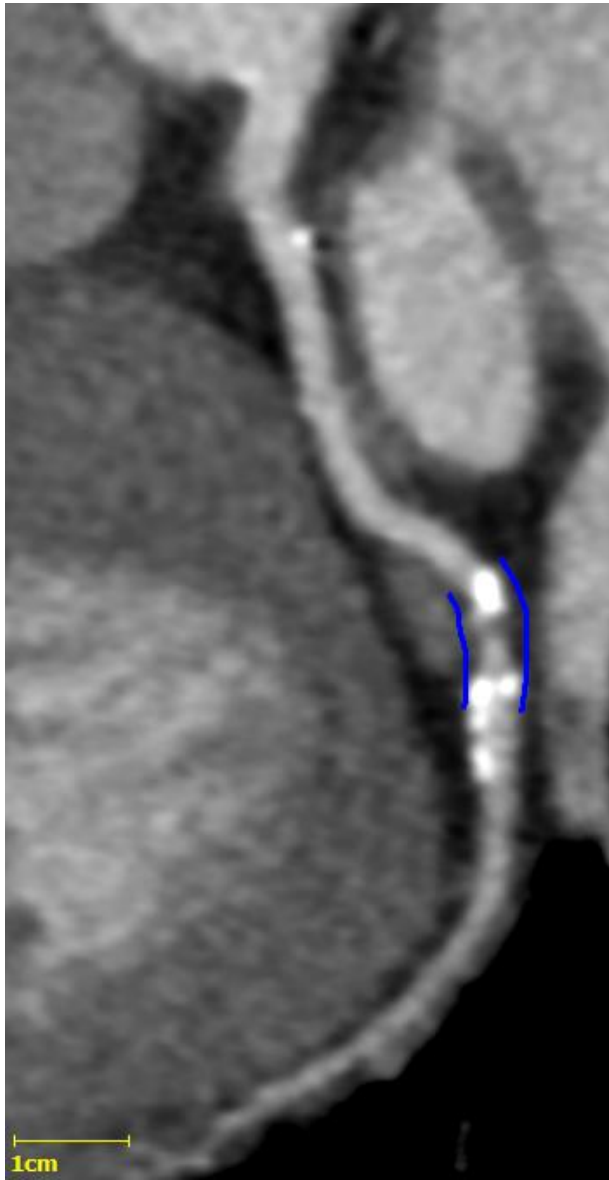



LCX:

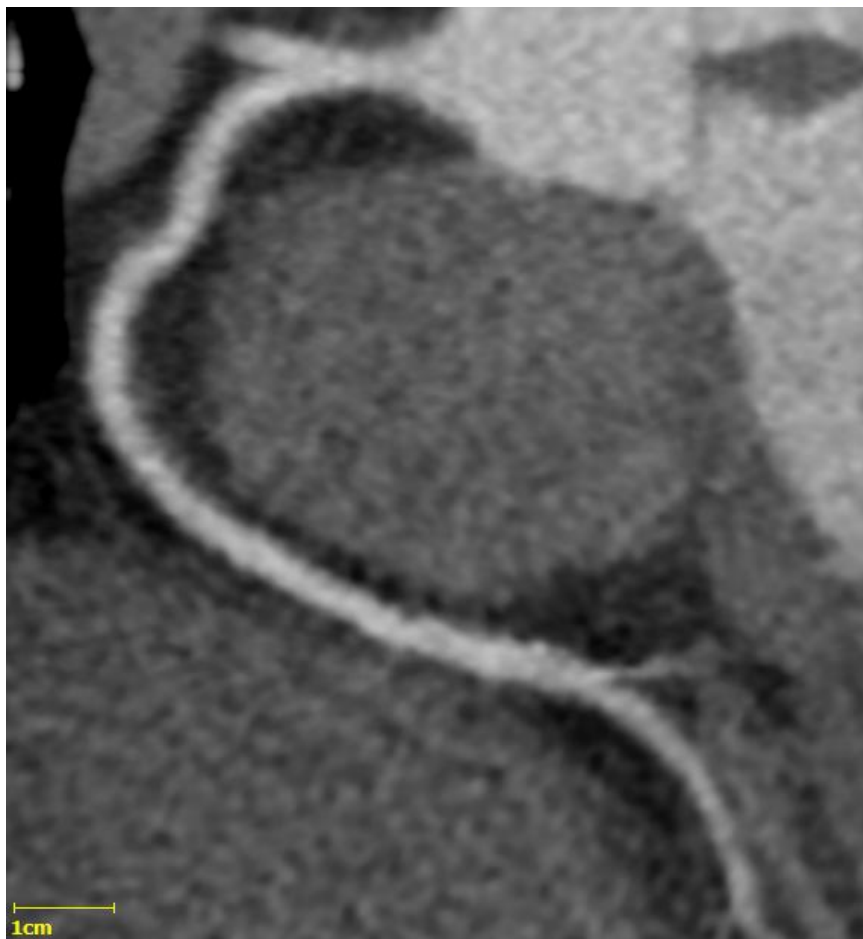
There is a Mixed plaque lesion causing 25-50% stenosis mid section.

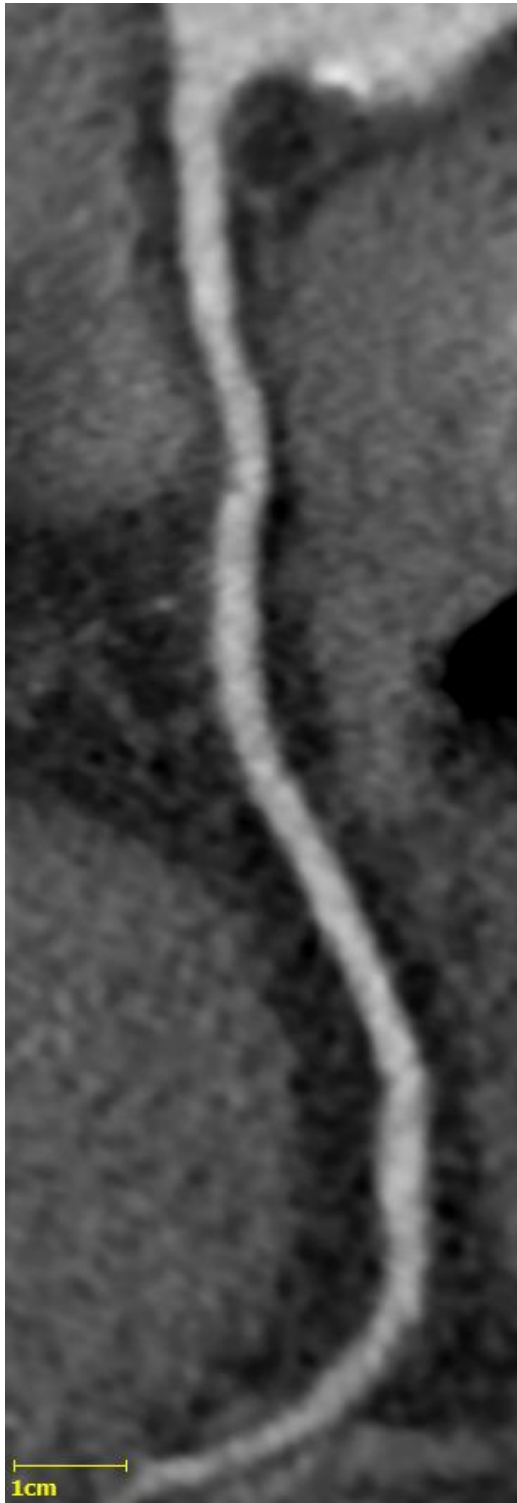




RCA:

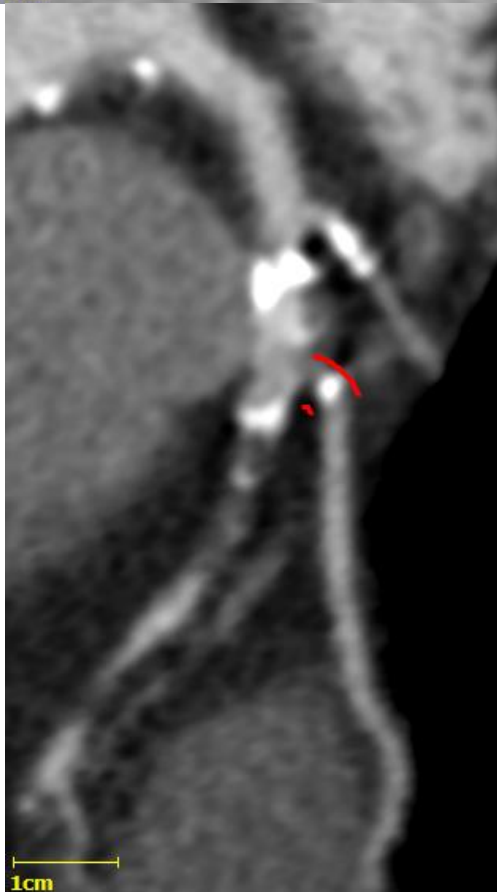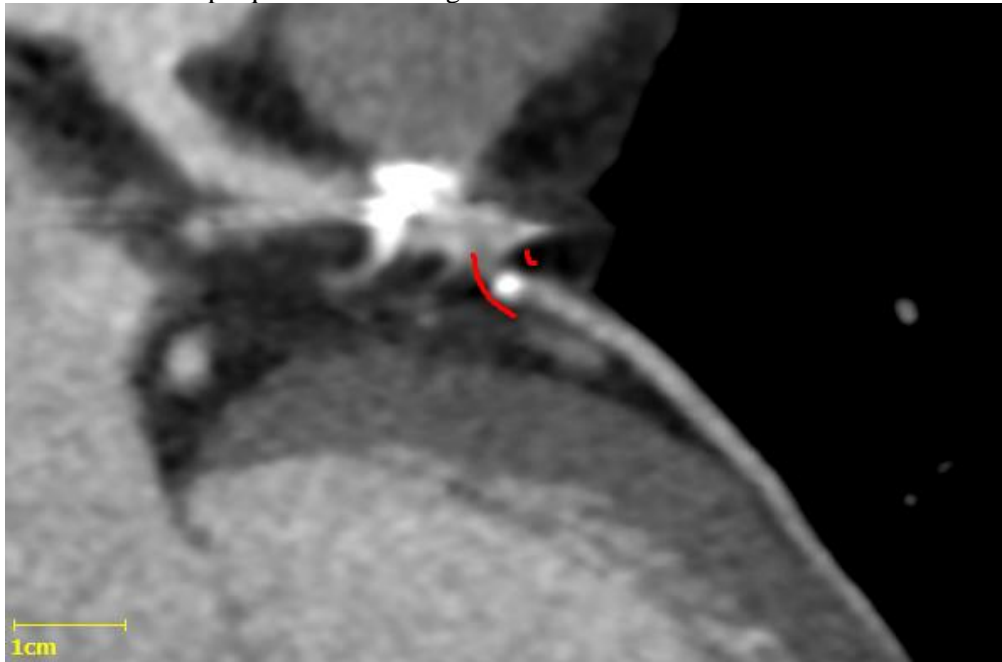There is no significant obstructive disease.





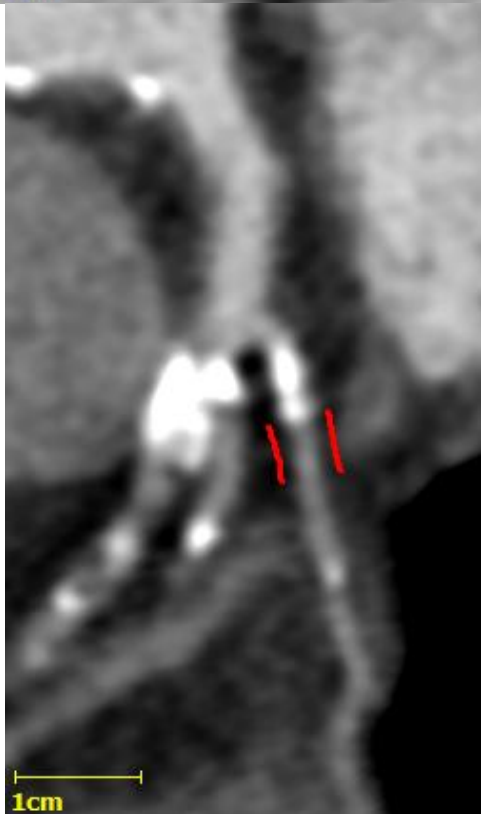
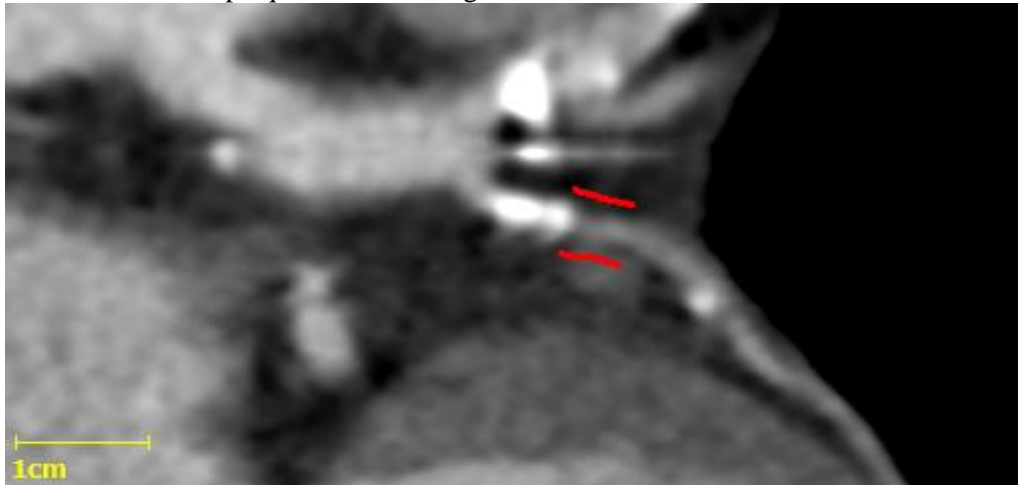
Diagonal.2:

There is a Mixed plaque lesion causing 50-75% stenosis .



Diagonal.1:

There is a non-CA plaque lesion causing >50% stenosis .





Extracardiac findings: (PLEASE NOTE - Only limited evaluation of extracardiac structures is possible due to small field of view.)

Mediastinum: There is no mediastinal adenopathy.

Lungs: The limited evaluation of the lungs reveal no abnormalities. There is no mass, infiltrate, or effusion. There is mild dependent subsegmental atelectasis bilaterally.

Aorta and pulmonary arteries: No evidence for a large central PE within visualized vessels. Aorta is grossly unremarkable.

Upper abdomen: The liver and other visualized upper abdominal organs are unremarkable.

Bones and Chest Wall: There are no lytic or blastic bone lesions. The chest wall is unremarkable.

Impression:

LAD: Plaque lesion causing 50-75% stenosis in LAD mid section

D1: Non-CA plaque lesion causing >50% stenosis in D1.

D2: Mixed plaque lesion causing 50-75% stenosis

LCx: Mixed plaque lesion causing 25-50% stenosis mid section.

Recommendation:

Further evaluation with conventional angiography.

Thank you for your kind referral.

-Electronically Signed by Michael Yuz, MD,
Diplomate, American Board of Radiology
Diplomate, Society of Cardiovascular Computed Tomography

Report Date: 11/24/2015

Report Time: 9:24 PM